



Written by [R. Cort Kirkwood](#) on June 4, 2020

Final Autopsy on Floyd: Bad Heart, Drug Use, COVID-19, “No Life-threatening Injuries”

The full autopsy report on George Floyd, the man who died while being restrained by Minneapolis policeman Derek Chauvin, confirms that Floyd took a highly dangerous narcotic and methamphetamine sometime before he died and suffered with an enlarged heart and high blood pressure.

The report also says Floyd had the Chinese Virus — COVID-19.

And although the Hennepin County, Minnesota, medical examiner concluded that the death was a “homicide,” the final autopsy confirms preliminary findings contained in the criminal complaint against Chauvin.

The final report does not mention asphyxia or strangulation and says Floyd did not sustain life-threatening injuries.

Key Findings

The final autopsy report says Floyd, 47, died of “cardiopulmonary arrest complicating law enforcement subdual, restraint, and neck compression,” as a [release from Hennepin’s coroner reported](#) a few days ago.

Floyd died on May 25 while Chauvin, 44, pinned him to the ground with a knee to the back of the neck for almost nine minutes, a few which passed after the 6-foot-7-inch Floyd stopped struggling. The criminal complaint against Chauvin [says Floyd](#) repeatedly resisted four officers who tried to arrest him for using a fake \$20 bill at a store.

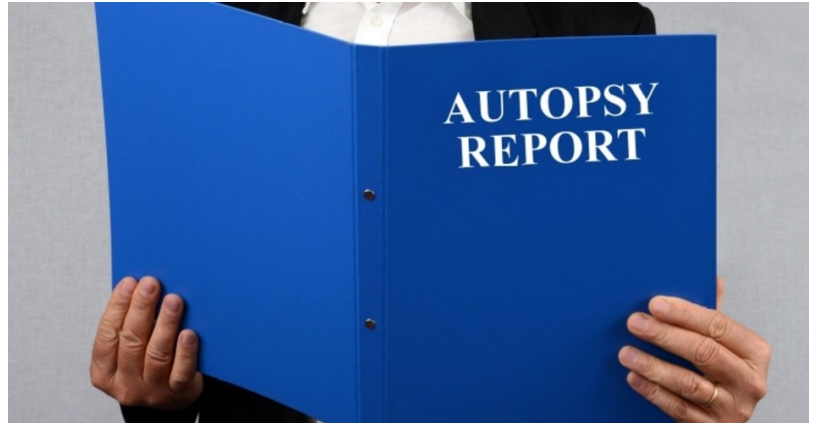
But more details in the [final autopsy report suggest](#) that Floyd’s underlying health likely contributed to his death.

Among Floyd’s “natural diseases” were “severe” coronary artery disease, high blood pressure, and hypertensive heart disease, the top cause of death from high blood pressure, the [WebMD website says](#). Floyd also suffered with cardiomegaly, an enlarged heart, and had a “clinical history of hypertension.” Floyd also used dangerous drugs, the [report says](#). The autopsy found fentanyl and methamphetamine in his bloodstream.

Fentanyl is a synthetic opioid pain reliever, the [Centers for Disease Control says](#), that is “50 to 100 times more potent than morphine.” Opioids are respiratory depressants.

[Floyd complained](#) that he couldn’t breathe before Chauvin pinned him to the ground.

Beyond the findings of serious heart disease and opioid use are those directly related to his fatal encounter with Chauvin.





Written by [R. Cort Kirkwood](#) on June 4, 2020

Floyd suffered multiple “blunt force” wounds, but “no life-threatening injuries [were] identified,” the [report says](#).

- A. No facial, oral mucosal, or conjunctival petechiae
- B. No injuries of anterior muscles of neck or laryngeal structures
- C. No scalp soft tissue, skull, or brain injuries
- D. No chest wall soft tissue injuries, rib fractures (other than a single rib fracture from CPR), vertebral column injuries, or visceral injuries
- E. Incision and subcutaneous dissection of posterior and lateral neck, shoulders, back, flanks, and buttocks negative for occult trauma

The absence of [petechiae](#) — small red or purple spots in the eyes or skin from bleeding capillaries — is significant because [they occur](#) in upwards of 85 percent of strangulation or traumatic asphyxia deaths; i.e., increased pressure on the neck of the kind that Chauvin applied to Floyd.

A nasal swab taken the day after Floyd died divulged the Chinese Virus infection.

Ellison Upgrades Charges, Other Officers in Jail

Celebrity pathologist Michael Baden, working for the Floyd family with a pathologist from the University of Michigan, [concluded differently](#) and said Floyd died of “asphyxia due to compression of the neck.”

That aside, the question is whether the men can get a fair trial given the circumstances and determination of state officials to see them convicted.

Minnesota Attorney General Keith Ellison, a hard-left Islamic radical and Antifa sympathizer [who says](#) the communist terror group is not behind the deranged violence in Minneapolis, took over the prosecution of Chauvin, then added a second-degree murder charge to the original charges of third-degree murder and manslaughter.

Ellison also charged the other officers at the scene, [Tou Thao](#), [Thomas K. Lane](#), and [J. Alexander Kueng](#), with aiding and abetting second-degree murder while committing a felony, and with aiding and abetting second-degree manslaughter with culpable negligence.

Ellison’s elevation to a position where he can prosecute others for crimes of violence is something of a strange turn.

In 2018, his former concubine’s son [took to Facebook](#) to accuse Ellison of domestic violence:

In the middle of 2017, I was using my mom’s computer trying to download something and I clicked on a file, I found over 100 text and twitters messages and video almost 2 min long that showed Keith Ellison dragging my mama off the bed by her feet, screaming and calling her a “f***ing bitch” and telling her to get the f*** out of his house.

Neither law enforcement nor Democratic Party officials did anything about it.

Image: Richard Villalon/iStock/Getty Images Plus

R. Cort Kirkwood is a long-time contributor to The New American and a former newspaper editor



Subscribe to the New American

Get exclusive digital access to the most informative,
non-partisan truthful news source for patriotic Americans!

Discover a refreshing blend of time-honored values, principles and insightful perspectives within the pages of "The New American" magazine. Delve into a world where tradition is the foundation, and exploration knows no bounds.

From politics and finance to foreign affairs, environment, culture, and technology, we bring you an unparalleled array of topics that matter most.



Subscribe

What's Included?

- 24 Issues Per Year
- Optional Print Edition
- Digital Edition Access
- Exclusive Subscriber Content
- Audio provided for all articles
- Unlimited access to past issues
- Coming Soon! Ad FREE
- 60-Day money back guarantee!
- Cancel anytime.